

## PIRIFORMIS SYNDROME

### The Piriformis Syndrome Is Overdiagnosed

JOHN D. STEWART, MB, BS, FRCP(C)

Department of Neurology and Neurosurgery, Montreal Neurological Hospital and McGill University, 3801 University Street, Room 365, Montreal, Quebec H3A 2B4, Canada

**C**onfusion reigns in the literature because the term piriformis syndrome (PS) has been used to denote four different entities. Which of these, if any, warrant the designation PS? Each will be discussed in turn.

**Damage to the Proximal Sciatic Nerve by Lesions in the Vicinity of the Piriformis Muscle.** Lesions of the proximal sciatic nerve in the area of the sciatic notch may occur from endometriosis, tumors, hematomas, fibrosis, aneurysms, false aneurysms, or arteriovenous malformations. Some authors have diagnosed such patients as having PS. Since the piriformis muscle plays no role in these situations, such causes of sciatic neuropathy are best included under the rubric "proximal sciatic neuropathies."

**Compressive Damage to the Proximal Sciatic Nerve by the Piriformis Muscle.** It has long been suggested that the proximal sciatic nerve can be compressed by the piriformis muscle where it crosses the nerve, and that the frequent anatomical variations occurring here predispose to this. Does such a condition exist? This author proposes that, ideally, the following five criteria need to be fulfilled to define such a syndrome: (1) Presence of symptoms and signs of sciatic nerve damage. (2) Presence of electrophysiological evidence of sciatic nerve damage. Paraspinal muscle electromyography (EMG) must be normal, to help in excluding a radiculopathy. (3) Imaging of the

lumbosacral nerve roots and of the paravertebral and pelvic areas must be normal to exclude radiculopathy, or lower lumbar or sacral plexus infiltration or damage. Imaging of the pelvis and sciatic notch must show the absence of mass lesions there. The significance of suspected abnormalities of the piriformis muscle seen on imaging is uncertain, as discussed later. (4) Surgical exploration of the proximal sciatic nerve should confirm an absence of mass lesions. Ideally, compression of the sciatic nerve by the piriformis muscle or associated fibrous bands should be identified. However, it can sometimes be difficult to recognize a compressed nerve. (5) Relief of symptoms and improvement in neurological abnormalities should follow surgical decompression. However, as in other situations of chronic nerve damage, decompression may not always lead to symptom relief. Further, as discussed later, surgical division of the piriformis muscle has been described, surprisingly, as relieving pain in patients with lumbosacral radiculopathies.

The older descriptions of alleged PS antedate modern imaging techniques, so these patients are excluded from further discussion. A few patients meet some of the criteria for PS, and a few others very nearly meet the criteria. In one of the latter, the surgical finding was a hypertrophied piriformis muscle compressing the sciatic nerve.<sup>7</sup> Three patients had bifid piriformis muscles compressing the lateral trunk of the sciatic nerve.<sup>2,4</sup> Two patients had nerve compression by fibrous bands associated with the piriformis muscle.<sup>4,8</sup>

**Damage to the Sciatic Nerve by the Piriformis Muscle and Adjacent Tissues from Trauma and Scarring.** Benson and Shuster<sup>1</sup> reported a series of patients with sciatic nerve lesions that they appropriately termed "post-traumatic PS." Symptoms began after blows to the buttocks. Several had electromyographic (EMG) studies showing abnormalities in muscles supplied by the sciatic and inferior gluteal nerves. One patient

This article was prepared and reviewed by the AAEM and did not undergo the separate review process of *Muscle & Nerve*.

**Abbreviations:** EMG, electromyography; MRI, magnetic resonance imaging; PS, piriformis syndrome

**Key words:** buttock pain; piriformis muscle; piriformis syndrome; sciatic nerve; sciatica

**Correspondence to:** American Association of Electrodiagnostic Medicine, 421 First Avenue SW, Suite 300 East Rochester, MN 55902, USA; e-mail: aaem@aaem.net

© 2003 American Association of Electrodiagnostic Medicine. Published by Wiley Periodicals, Inc.

had myositis ossificans of the piriformis muscle, confirmed at operation. Others had adhesions between the piriformis muscle, the sciatic nerve, and the roof of the sciatic notch. One patient had an anatomical anomaly of the sciatic nerve and piriformis muscle. All patients had a release of the piriformis tendon and their symptoms improved.

**Chronic Buttock Pain with No Evidence of Sciatic Nerve Damage.** There are many reports of patients with the primary symptom of buttock pain (often with “sciatica”) but no neurological deficits. In some, the symptoms followed buttock trauma. These patients do not meet the criteria outlined above. They are labeled as having PS based on the belief that their symptoms are due to impingement on the proximal sciatic nerve by the piriformis muscle.

The core issue here is the likelihood of chronic, or chronically recurrent compression of a peripheral nerve producing pain but no manifestations of nerve fiber damage. In clear-cut compressive neuropathies, pain from nerve trunk involvement is almost always accompanied by sensory or motor symptoms, clinical deficits, and electrophysiological abnormalities. When this combination of features is absent (e.g., in the “disputed neurological” thoracic outlet syndrome and resistant tennis elbow syndrome), there is little convincing evidence that nerve trunks are involved in the genesis of symptoms.

A frequent accompaniment of the buttock pain in this group of patients is sciatica. Most would accept a definition for this term as being pain radiating down the leg from the lower back, buttock, or hip. Notwithstanding its name, such pain is not a specific indicator of sciatic nerve involvement. The most frequent neurological cause is L-5 or S-1 radiculopathy; others include lower lumbar and sacral plexopathy and proximal sciatic neuropathies. Non-neurological causes are more frequent and include musculoskeletal abnormalities of the lumbosacral spine and hip, and pelvic disease.

Much of the so-called evidence for this type of “PS” rests on a variety of physical signs said to demonstrate pinching of the sciatic nerve by the piriformis muscle during certain leg and hip maneuvers. These signs are all of doubtful validity in terms of specifically demonstrating compression of the sciatic nerve by the piriformis muscle. Several classic signs in medicine have been shown to have poor sensitivity and specificity; for instance, Tinel’s and Phalen’s signs for carpal tunnel syndrome, and Adson’s maneuver for thoracic outlet syndrome. No sign said to indicate PS has been critically evaluated. Tenderness on deep palpation in the buttock is often found in

patients with conditions such as lumbosacral radiculopathy, tumors or other masses at the sciatic notch, and posttraumatic scarring in this area. Tenderness therefore does not reliably indicate an abnormality of the piriformis muscle.

Further so-called evidence that the piriformis muscle plays a role in these patients is the occurrence of pain relief following local anesthetic or corticosteroid injections into the piriformis muscle and sciatic notch area. Unfortunately, this does not elucidate the underlying pathology. Such injections will tend to relieve local symptoms regardless of the cause. Moreover, it is well established that nerve blocks distal to a nerve lesion can produce pain relief.<sup>5</sup> Deep buttock injections have been shown to relieve pain in patients with lumbosacral radiculopathies and carcinomatous sacral root infiltration. One extraordinary study found that division of the piriformis muscle in patients with lumbosacral radiculopathies produced pain relief.<sup>6</sup> Thus, improvement of pain from injections and even from surgical division of the piriformis muscle cannot be used as proof of sciatic nerve compression at that site.

The reports of a swollen piriformis muscle or abnormal signals in that muscle as seen on computerized tomography scanning or magnetic resonance imaging (MRI) are difficult to interpret. Do such so-called abnormalities occur occasionally as incidental findings in otherwise normal persons?

**The Fishman Study.** In 2002, Fishman and colleagues<sup>3</sup> reported a series of 918 patients (1014 legs) with alleged PS. These investigators made a valiant attempt to create diagnostic criteria, to validate an electrophysiological test demonstrating sciatic nerve dysfunction, as well as to evaluate a nonsurgical treatment protocol and results of surgery. Unfortunately, there are serious flaws in their methodology. The entry criteria consisted of nonspecific symptoms and signs. Exclusionary criteria (imaging abnormalities of the lower spine and pelvis) were not described. Standard electrophysiological studies of sciatic nerve function were not performed. The H-reflex testing protocol used was based on normal values derived from volunteers who may not have been age-matched to the patients. Treatments were broad-based and could benefit patients with a variety of painful musculoskeletal disorders of the lower spine, pelvis, and hips. Some treatment measures and their alleged effects were implausible; for instance, “myofascial release at the lumbosacral paraspinal muscles” and “conservative treatment that lengthens the piriformis muscle.” Most patients, regardless of the number of clinical criteria for PS, and whether the

H-reflex test was abnormal or not, responded well to nonsurgical therapy. The statistical results are difficult to interpret. In summary, their study, regrettably, neither defined a distinct syndrome nor clarified any of the issues surrounding PS.

### CONCLUSIONS

There remains no consensus as to how to use the term PS, let alone whether there is an entity deserving of this appellation. Sciatic nerve lesions from masses in the region of the sciatic notch and piriformis muscle should be designated as proximal sciatic neuropathies; to use the term PS misleadingly implies a pathogenic role for the piriformis muscle. There is certainly a rare syndrome of proximal sciatic nerve damage by compression from the piriformis muscle or associated fibrous bands. Sometimes this is associated with an anatomical anomaly of the piriformis muscle and sciatic nerve. The term PS is apt here. When such a condition occurs following buttock trauma, it is reasonable to designate this as posttraumatic PS.

It is unlikely that the piriformis muscle plays a pathogenic role in most patients with buttock pain (with or without sciatica) yet no clinical or electrophysiological evidence of sciatic nerve damage, and in whom imaging studies of the lumbosacral spine and pelvis are normal. The use of the term PS here is therefore strongly discouraged. In such patients a diligent search for alternative causes of their pain should be undertaken. If no abnormalities are

found, the patient should be treated symptomatically. However, it is impossible to know which of the many conservative measures described, including local anesthetic and corticosteroid injections into the piriformis area, are likely to be beneficial. The indications for, and the outcome from, surgical exploration and division of the piriformis muscle in these patients are entirely uncertain.

Dr. Gillian Bartlett-Esquillant of the Department of Medicine, McGill University, provided valuable help with this study.

---

### REFERENCES

1. Benson ER, Schutzer SF. Posttraumatic piriformis syndrome: diagnosis and results of operative treatment. *J Bone Joint Surg Am* 1999;81:941-949.
2. Chen WS. Bipartite piriformis muscle: an unusual cause of sciatic nerve entrapment. *Pain* 1994;58:269-272.
3. Fishman LM, Dombi GW, Michaelsen C, Ringel S, Rozbruch J, Rosner B, Weber C. Piriformis syndrome: diagnosis, treatment, and outcome—a 10-year study. *Arch Phys Med Rehabil* 2002; 83:295-301.
4. Hughes SS, Goldstein MN, Hicks DG, Pellegrini VD. Extrapelvic compression of the sciatic nerve. An unusual case of pain about the hip: report of five cases. *J Bone Joint Surg Am* 1992;74:1553-1559.
5. Kibler RF, Nathan PW. Relief of pain and paraesthesiae by nerve block distal to a lesion. *Neurol Neurosurg Psychiatry* 1960;23:91-98.
6. Mizuguchi T. Division of the piriformis muscle for the treatment of sciatica. Postlaminectomy syndrome and osteoarthritis of the spine. *Arch Surg* 1976;111:719-722.
7. Stein JM, Warfield CA. Two entrapment neuropathies. *Hosp Pract (Off Ed)* 1983;18:100A, 100E, 100H.
8. Vandertop WP, Bosma NJ. The piriformis syndrome. A case report. *J Bone Joint Surg Am* 1991;73:1095-1097.

---

## The Piriformis Syndrome Is Underdiagnosed

LOREN M. FISHMAN, MD,<sup>1</sup> and MICHAEL P. SCHAEFER, MD<sup>2</sup>

<sup>1</sup> Department of Rehabilitation, Columbia University, New York, New York, USA

<sup>2</sup> Mayo Clinic, 200 First Street, Rochester, Minnesota 55905, USA

**P**iriformis syndrome (PS) is a functional entrapment of the sciatic nerve or its branches as they leave the pelvis in relation to the piriformis muscle. It has been variously ascribed to anatomical variance, and vascular, traumatic, and mechanical causes, and is believed by some to be totally illusory. What is generally accepted as PS are cases of sciatica in which the pathogenetic mechanism is pressure-dependent stress on the sciatic nerve by the piriformis muscle.

Contending that a condition is underdiagnosed is self-defeating and doomed from the start. To

prove that a condition is underdiagnosed, it is necessary to identify cases of the condition that have not already been identified. Of course, once identified, there is no longer any reason to say that the condition is underdiagnosed. There is no rogue's gallery of suspects that have never been photographed.

Also, it is in no way paradoxical for the same condition to be overdiagnosed and underdiagnosed at the same time (see Fig. 1). "Underdiagnosed" simply means there are examples of the condition that are unrecognized. A condition is overdiagnosed

to the extent that there are people said to have the condition who really do not. Conditions can be simultaneously under- and overdiagnosed when neither the set of actual cases nor the set of diagnosed cases completely contains the other set. If the set of diagnosed cases is smaller than the set of actual cases, then there are more underdiagnosed than overdiagnosed cases. For every case diagnosed that is not an actual case (overdiagnosed), there is one case that is actual and not diagnosed (underdiagnosed), plus at least one other underdiagnosed case. Boundaries of the two sets converge as diagnostic tests more faithfully reflect the pathogenetic mechanism (see arrow in Fig. 1). Even further, PS may be overdiagnosed by individuals or groups at one time, and underdiagnosed by individuals or groups at another time. The extent to which PS is under- and overdiagnosed may be due to its being considered a “diagnosis of exclusion.” Unless and until all other likely candidates are excluded, it may not generally be considered (underdiagnosed). However, when all other seemingly reasonable diagnoses have been excluded, it may be applied too hastily (overdiagnosed).

We attempt to present two kinds of evidence that PS is widely underdiagnosed: (1) inductive evidence; and (2) as close to deductive evidence as is possible in an empirical science.

**Inductive Evidence.** Using empirical evidence to support the underdiagnosis of PS requires a method that: (1) establishes an acceptable definition; (2) shows that treatment directed to the piriformis muscle significantly helps people whose condition matches the definition; (3) examines an unbiased sample of the population to estimate the incidence of PS by that definition; and (4) determines that the percentage of cases identified is smaller than the estimate.

**Finding a Definition and Meeting It.** Even in 15th century Florence, many practitioners found clinical cases of PS using a broad array of definitions. In recent times, more than 20 series have been reported, using different clinical criteria, but generally including pain on deep palpation of the point of intersection of muscle and nerve, a positive Lasègue sign, and pain on resisted abduction or passive abduction of the flexed thigh.

Operational definitions have included reproduction of the pain with digital intraanal or intravaginal palpation; sausage-like mass within the body of the piriformis muscle; and prolongation of the H reflex

with flexion, adduction, and internal rotation (FAIR test). Contemporary studies cite more than 1500 patients in toto.

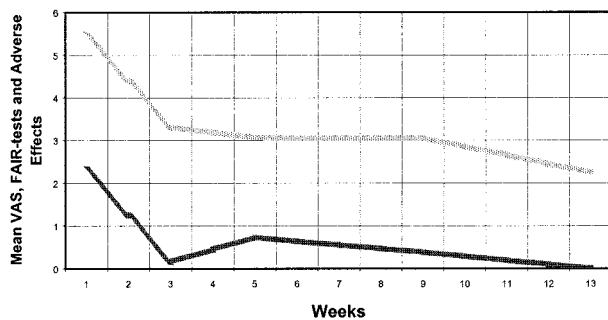
In order to reduce error in identifying patients, and to delimit their intervention’s focus, investigators frequently exclude what may be legitimate cases that have other conditions that might produce sciatica. For example, Childers and colleagues recently excluded patients with imaged herniated disk, nerve root impingement, or electromyographic evidence of denervation proximal to the sciatic notch.<sup>2</sup>

Because of exposure in the lay press, the authors have seen over 3000 patients who have come in on their own or been referred for suspected PS—hardly an unbiased sample. After examining and following these patients for an average of more than 1 year, the authors believe that approximately half of them actually did have PS. The means of diagnosing the patients and treating those diagnosed with PS has changed over time. Summing up 15 years of experience, the clinical criteria used were pain in the buttock and usually some part of the course of the sciatic nerve distal to it, tenderness in the region of intersection of the piriformis muscle and the sciatic nerve, and positive straight leg raise at 15° less than on the unaffected side, or less than 60° when PS was bilateral.

Electrophysiological criteria were prolongation (>3SD) of the posterior tibial or peroneal H reflexes through the FAIR test, which has been described earlier.<sup>5</sup> Although not always seen to mirror clinical progress, electrophysiological criteria have shown greater than 83% sensitivity and specificity, when matched against these clinical criteria.<sup>2,4</sup>

At first, only patients that had negative computerized tomography (CT) imaging studies were considered, with no evidence of denervation in the paraspinal musculature, the tensor fascia latae, or any muscles with a nerve supply not part of the sciatic nerve distal to the piriformis muscle.<sup>5</sup> Later, a strong correlation was found between the electrophysiological and clinical criteria, and FAIR test prolongation of the H reflex was shown to correspond to the level of patients’ pain. This suggested a mechanical and generally reversible compression of the nerve by the muscle, a straightforward pathogenesis that of course could coexist with other types of pathology. At that point the authors’ clinic began considering patients with herniated disks, spondylolisthesis, spinal stenosis, and neuropathies, diagnosing PS in patients with comorbidity.<sup>4</sup>

**Successful Treatment Directed to the Pathogenetic Mechanism.** Once identified, patients have been treated surgically and conservatively.<sup>2,4,5,8</sup> Surgery



**FIGURE 1.** Mean visual analog scale, FAIR tests, and adverse effects following treatment with botulinum toxin, type B (grey line). Parallel movement of patients' symptoms (VAS) and FAIR-test values (solid line) promptly after injection suggests that the clinical symptoms were related to sciatic nerve compression by the piriformis muscle, which caused the H-reflex delay.

generally consists of neurolysis or excision in the approximately 15% of cases in which part or all of the sciatic nerve passes between or above the muscle. Surgical reports confirm at least a 75% success rate [50% or greater improvement in visual analog scale (VAS)]. Considering that an injured sciatic nerve can require a good deal of time to repair itself or be permanently damaged, these surgical results should be considered excellent, and equally excellent evidence that the syndrome is real. The fact that anatomical abnormalities are present in only 15% of instances at surgery, the same percentages seen in randomly gathered cadavers, suggests that the anatomical anomaly is not responsible for PS.

Physical therapy (PT) alone, focusing fairly narrowly on removing this mechanical compression, led to a minimum 50% reduction in symptoms in 60% of the cases we identified.<sup>4</sup> Injection, usually of lidocaine and corticosteroid or botulinum toxin, has brought from 40% to 90% improvement by the same criteria, the higher numbers reflecting PT and injection—again, specifically targeting the piriformis muscle.

There is some controversy about how to pinpoint the piriformis muscle for injection. Childers and colleagues used a combination of radiotracer and electromyographic activity on external rotation, representing the two standard methods used to verify needle placement.<sup>2</sup> Although these researchers did not see any change in H-reflex latencies (FAIR test) after injection, we observed significant decrements after conservative therapy and in pre- and postoperative testing.

Another study using EMG guidance for injection of botulinum toxin type B showed a 77% correlation coefficient between the VAS and the FAIR test results over a 3-month period (Fig. 1).<sup>3</sup> The diagnostic criteria that were met and the patients' symptoms disappeared at the same rate with treatment centered on the piriformis muscle.

Of course, there are cases of tightness of the piriformis muscle without nerve compression, and compression of the sciatic nerve may occur by other structures. However, it is unlikely that either of these situations would cause the clinical symptoms and signs, prolongation of the H reflex with flexion, adduction, and internal rotation, and benefit from therapy, injection, and surgery directed at reducing pressure of that muscle on that nerve.

#### *Incidence of PS in an Unbiased Sample of Sciatica.*

Incidence rates of PS vary from 33% to 36%.<sup>6</sup> Using absence of other findings and ipsilateral painful rectal examination as the definitive test, clinicians expert in back pain at the Mayo Clinic estimated that PS comprised 6% of 910 serial cases of sciatica.<sup>7</sup>

*Cases Diagnosed Are a Smaller Percentage of the Population Than the Percentage of Actual Cases.* Olmsted County, Minnesota, where the Mayo Clinic is located, recorded 32,655 cases of lower back pain in the years 1976–2001. The diagnosis of PS was made 220 times over this period, giving a diagnostic rate of 0.7%. In 1976–1979, the diagnosis was made in 11 of 4416 cases, a rate of 0.25%, whereas in 2000–2001 it was made in 54 of 4349 cases (1.24%), showing nearly a fivefold rise over this quarter century, but still fivefold short of the 6% seen in an unbiased sample by experts in that county. Walter Reed Hospital reported 155 cases of PS (1.58%) out of 9161 diagnoses of low back pain during the year 2002.

In New York, the 3895 patients the authors diagnosed with PS from 1992 to 2001 had been suffering from sciatica for an average of 6.2 years and had seen, on average, 6.55 other clinicians. Moreover, analysis of a 1014-leg study found that these 958 patients had 1190 magnetic resonance imaging scans, 1380 X-ray studies, 860 other imaging studies (bone scan, ultrasound, etc.), over 400 total surgeries (spinal, hip, and gynecological, in that order), and a large number of other procedures (such as prolotherapy and epidurals), suggesting that many of the previous clinicians considered PS a diagnosis of exclusion, or did not consider it at all.<sup>4</sup> More than 79% of these patients improved by greater than 50% with the focused treatment described above, with 66% of the conservative treatment failures improving by 50% or more if they subsequently chose surgery on the piriformis muscle.

Given the Agency for Health Care Policy and Research estimate that there are 80 million cases of sciatica and low back pain annually, our cases represent only a small sample of the annual cases, and the vast reservoir of undiagnosed cases that have built up over the years.<sup>1</sup> The additional fact that these patients required such efforts by the medical commu-

nity to receive what appears to have been the proper diagnosis suggests systematic underdiagnosis. This by no means assures that PS is not also overdiagnosed. All that is implied is that the total number of diagnosed cases is less than the calculated number of actual cases, and that therefore some actual cases are undiagnosed.

**Deductive Reasoning.** If one can define a class of disorders that are underdiagnosed, and of which PS is a member, there will be good deductive evidence that PS is underdiagnosed. Functional entrapments are a generally unrecognized group of ailments and include some cases of thoracic outlet syndrome, pronator syndrome, supinator syndrome, medial epicondylitis, and PS. This group can be defined by a focal reduction of conduction metrics (e.g., nerve conduction velocity, distal latency, evoked potential amplitude, H-reflex latency) resulting from mechanical pressure, and reversible by changes in position of the person or part of the person.

PS is an excellent example of this class of functional entrapment syndromes, which cause pain, paraesthesias, numbness, and episodic weakness. Imaging studies and even conventional electromyograms (EMGs) are generally normal, because the symptoms and signs are due to nerve compression that occurs in specific, generally common positions or circumstances, but not in the anatomical position in which these tests are commonly performed. In the case of PS, sitting and running most frequently produce the characteristic buttock pain with or without sciatica. Thoracic outlet syndrome often becomes symptomatic when the arms are raised overhead. Entrapment of the ulnar nerve by the lateral head of the flexor carpi ulnaris occurs with radial deviation of the wrist, for instance, when ironing clothes. Because EMG testing rarely includes functional maneuvers, it is likely that functional entrapments are largely under-

diagnosed. PS is a functional entrapment. Therefore, it is likely that PS is underdiagnosed.

The only way out of this syllogism is to deny one of the premises. Or, one might maintain that, yes, it would be an underdiagnosed class if there were any cases, but in fact there are not. The inductive evidence given above suggests that: (1) there are cases; and (2) in general, clinicians are not looking hard enough for the diagnosis.

Clinical suspicion of PS should rise when the patient has more pain sitting than standing; a history of overuse, trauma, or unusual body habitus (obesity or cachexia); or tenderness in the mid-buttock that resembles their initial complaint. Once PS is appropriately sought by clinicians, and rationally linked to a test that replicates its pathogenetic mechanism, PS can be properly diagnosed or excluded according to the skill and energy of individual practitioners. At that point, a great deal of the systematic error that brings about underdiagnosis will have been eliminated.

---

#### REFERENCES

1. Agency for Health Care Policy and Research. Acute low back problems in adults. Clinical practice guidelines no. 14. AHCPR publication no. 95-0642. Rockville, MD: Department of Health and Human Services; 1994.
2. Childers MK, Wilson DJ, Gnatz SM, Conway RR, Sherman AK. Botulinum toxin in piriformis muscle syndrome. *Am J Phys Med Rehabil* 2002;81:751-759.
3. Fishman LM, Anderson C, Rosman B. Botox and physical therapy in the treatment of piriformis syndrome. *Am J Phys Med Rehabil* 2002;81:936-942.
4. Fishman LM, Dombi GW, Michaelsen C, Ringel S, Rozbruch J, Rosner B, Weber C. Piriformis syndrome: diagnosis, treatment, and outcome—a ten-year study. *Arch Phys Med Rehabil* 2002; 83:295-301.
5. Fishman LM, Zybert PA. Electrophysiological evidence of piriformis syndrome. *Arch Phys Med Rehabil* 1992;73:359-364.
6. Foster MR. Piriformis syndrome. *Orthopedics* 2002;25:821-825.
7. Hallin RP. Sciatic pain and the piriformis muscle. *Postgrad Med* 1983;74:69-72.
8. Mizuguchi T. Division of the piriformis muscle for the treatment of sciatica. *Arch Surg* 1976;111:719-722.